

## PCR Detection of *Scopulariopsis brevicaulis*

MILENA KORDALEWSKA and ANNA BRILLOWSKA-DĄBROWSKA\*

Molecular Biotechnology and Microbiology Department, Faculty of Chemistry  
Gdańsk University of Technology, Gdańsk, Poland

Submitted 9 July 2014, revised 5 November 2014, accepted 13 November 2014

### Abstract

*Scopulariopsis brevicaulis* is known as the most common etiological factor of the mould toenail infections. There are also reports indicating that *S. brevicaulis* could cause organ and disseminated infections. Nowadays microscopic observations from the direct sample and culture are crucial for the appropriate recognition of the infection. In this paper a PCR-based method for *S. brevicaulis* detection is presented. The specificity of the reaction was confirmed, as positive results were obtained only for tested *S. brevicaulis* isolates and no positive results were obtained for other moulds, dermatophytes, yeast-like fungi, and human DNA.

**Key words:** *Scopulariopsis brevicaulis*, onychomycosis, PCR

*Scopulariopsis brevicaulis* is a soil saprophytic mould. This non-dermatophytic filamentous fungus colonises plantar, animal and human tissues (Filipello Marchisio *et al.*, 2000). Traditionally, it has not been considered a common human pathogen. However, the number of cases showing its pathogenicity is still increasing. The most common type of infection caused by *S. brevicaulis* is onychomycosis. Its prevalence is estimated to be 3–10% of total number of onychomycosis cases. The clinical manifestation is generally recognised as distal and lateral subungual onychomycosis (DLSO) (Stefanato and Verdolini, 2009; Gupta *et al.*, 2012). There are also cases of smooth skin and subcutaneous tissue infections caused by *S. brevicaulis* (Dhar and Carey, 1993; Bryuynzel and Starink, 1998; Anandan *et al.*, 2008). Moreover, *S. brevicaulis* has been reported as the cause of such infections as endocarditis (Gentry *et al.*, 1995; Migriono *et al.*, 1995; Jain *et al.*, 2011), keratitis (Del Prete *et al.*, 1994; Lotery *et al.*, 1994), endophthalmitis (Gariano and Kalina, 1997), sinusitis (Gluck *et al.*, 2011), fungus ball (Endo *et al.*, 2002; Satyavani *et al.*, 2010), otomycosis (Hennequin *et al.*, 1994; Besbes *et al.*, 2002), pneumonia (Issakainen *et al.*, 2010), cerebral phaeohyphomycosis and brain abscess (Hart *et al.*, 2001), disseminated infection causing skin lesions including a patient with acquired immune deficiency syndrome (AIDS) (Dhar and Carey, 1993), disseminated infections after bone marrow transplant (Neglia *et al.*, 1987; Phillips *et al.*, 1989; Krisher *et al.*,

1995) and after lung transplant (Wuyts *et al.*, 2005). Disseminated *S. brevicaulis* infections are hard to treat and have high mortality rates, especially in immunocompromised patients. *S. brevicaulis* disseminated infections might be clinically and histologically indistinguishable from disseminated aspergillosis, fusariosis or zygomycosis (Salmon *et al.*, 2010; Swick *et al.*, 2010; Vignon *et al.*, 2011). The data considering *S. brevicaulis* susceptibility are scarce and often inconsistent. The reports indicate that *S. brevicaulis* is a multi resistant fungus (Cuenca-Estrella *et al.*, 2003).

In this paper we present a PCR-based method developed for the detection of *S. brevicaulis*. By a two-step extraction procedure followed by PCR and electrophoresis, the method enables fast identification of this pathogen.

Reference strains: *S. brevicaulis* (CBS 112377), *Scopulariopsis fusca* (IHEM 14552; IHEM 25912), *Scopulariopsis asperula* (IHEM 2546), *Scopulariopsis cinerea* (IHEM 25417) and other fungal isolates were obtained from the Microbiology Department of Gdańsk University of Technology (Poland). Three animal (rabbit)-derived *S. brevicaulis* isolates (isolated from superficial infections) were obtained from the Department of Pre-clinical Sciences of Warsaw University of Life Sciences (Poland). One human-derived *S. brevicaulis* isolate (isolated from superficial infection) was obtained from the Department and Clinic of Dermatology, Venereology and Allergology of Wrocław Medical University

\* Corresponding author: A. Brillowska-Dąbrowska, Molecular Biotechnology and Microbiology Department, Faculty of Chemistry, Gdańsk University of Technology, Gdańsk, Poland; e-mail: [annbrill@pg.gda.pl](mailto:annbrill@pg.gda.pl)

(Poland) (Table I). All isolates were identified by observation of macro- and micromorphology. Isolates were cultured on Sabouraud medium (Biomérieux, France) and incubated for up to 14 days at room temperature. DNA from samples (pieces of mycelium of 3–5 mm diameter) was extracted by a 10-min incubation of the sample in 100 µl of extraction buffer (60 mM sodium bicarbonate [NaHCO<sub>3</sub>], 250 mM potassium chloride [KCl] and 50 mM Tris, pH 9.5) in 95°C and subsequent addition of 100 µl anti-inhibition buffer (2% bovine

serum albumin). After vortex mixing, this DNA-containing solution was used for PCR (Brillowska-Dąbrowska *et al.*, 2010). Reagents were, unless otherwise stated, purchased from Sigma (Germany).

On the basis of alignment (VectorNTI; InforMax, Inc., USA) of sequences of β-tubulin gene presented in the NCBI nucleotide database, *S. brevicaulis* – specific primers Sbfor (5'ACAAACCCACTTCCCGTCGTTT3') and Sbrev (5'ACATATTTGTTTCCCGAAGCCTTTAG3') were designed. One *S. brevicau-*

Table I  
Organisms used in the study (161 isolates)

Organism		No of isolates	Organism		No of isolates	
moulds	<i>Scopulariopsis brevicaulis</i> (reference strain)	1	moulds	<i>Pleospora papaveracea</i>	1	
	<i>S. brevicaulis</i> (clinical isolates)	4 (1 human-derived) (3 animal-derived)		<i>Rhizopus oryzae</i>	1	
	<i>S. fusca</i> (reference strain)	2		<i>R. oligosporus</i>	1	
	<i>S. cinerea</i> (reference strain)	1		<i>Trichoderma viridae</i>	1	
	<i>S. asperula</i> (reference strain)	1		<i>Ulocladium tuberculatum</i>	1	
	<i>Acremonium charticola</i>	1		<i>U. chartarum</i>	1	
	<i>A. kiliense</i>	1	dermato- phytes	<i>Epidermophyton floccosum</i>	7	
	<i>Alternaria strictum</i>	1		<i>Microsporium audouinii</i>	5	
	<i>Alternaria alternata</i>	6		<i>M. canis</i>	3	
	<i>A. brassicae</i>	3		<i>M. gypseum</i>	5	
	<i>A. tenuissima</i>	1		<i>M. nanum</i>	1	
	<i>Alternaria sp.</i>	1		<i>M. persicolor</i>	3	
	<i>Aspergillus flavus</i>	2		<i>Trichophyton equinum</i>	1	
	<i>A. fumigatus</i>	8		<i>T. erinacei</i>	2	
	<i>A. clavatus</i>	3		<i>T. interdigitale</i>	4	
	<i>Cladosporium cladosporioides</i>	2		<i>T. mentagrophytes</i>	5	
	<i>C. macrocarpum</i>	1		<i>T. rubrum</i>	4	
	<i>Fusarium solani</i>	1		<i>T. schoenleinii</i>	3	
	<i>F. oxysporum</i>	1		<i>T. soudanense</i>	2	
	<i>F. culmorum</i>	1		<i>T. terrestrae</i>	6	
	<i>Mucor racemosus</i>	2		<i>T. tonsurans</i>	6	
	<i>M. circinelloides</i>	1		<i>T. verrucosum</i>	5	
	<i>Ochrocladosporium elatum</i>	1		<i>T. violaceum</i>	3	
	<i>Penicillium chrysogenum</i>	1		yeast-like fungi	<i>Candida albicans</i>	7
	<i>P. commune</i>	2			<i>C. catenulata</i>	1
	<i>P. melinii</i>	1			<i>C. glabrata</i>	3
	<i>Penicillium sp.</i>	1	<i>C. guillermondii</i>		1	
	<i>P. digitatum</i>	1	<i>C. kefyr</i>		2	
	<i>P. italicum</i>	1	<i>C. krusei</i>		1	
	<i>P. polonicum</i>	1	<i>C. magnoliae</i>		1	
	<i>P. crustosum</i>	1	<i>C. parapsilosis</i>		5	
	<i>P. verrucosum</i>	1	<i>C. tropicalis</i>		5	
<i>P. paneum</i>	1	<i>C. utilis</i>	1			
<i>P. hirsutum</i>	1	<i>Geotrichum sp.</i>	1			
<i>P. carneum</i>	1	<i>Rhodotorula mucilaginosa</i>	1			
		<i>Saccharomyces cerevisiae</i>	1			
		Human	1			

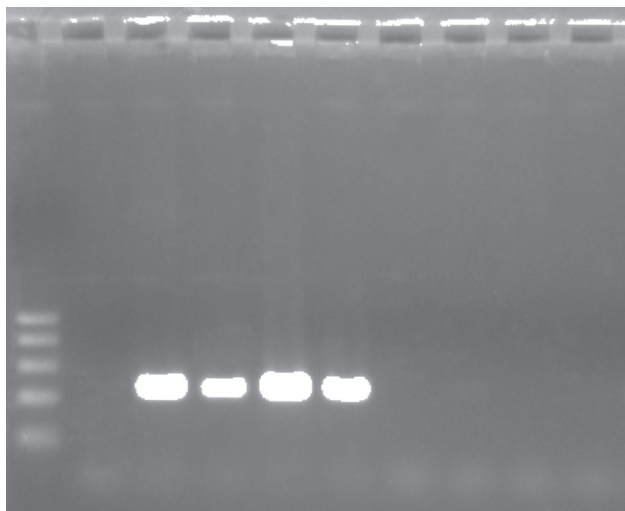


Fig. 1. Example of *S. brevicaulis* specific PCR product analysis. Lane 1 – molecular size marker (fragment sizes 500, 400, 300, 200 and 100 bp); results of *S. brevicaulis*-specific PCR performed for *S. brevicaulis* – reference strain (lane 3), human-derived isolate (lane 4), animal-derived isolates (lanes 5–6); *S. fusca* – reference strains (lanes 7–8); *S. asperula* (lane 9); *S. cinerea* (lane 10); negative control (lane 2).

*lis* reference strain, four clinical *S. brevicaulis* isolates, two *S. fusca* reference strains, one *S. asperula* reference strain, one *S. cinerea* reference strain and 56 other mould isolates, 65 dermatophyte isolates, 30 yeast-like isolates and one purified human DNA (Table I) were tested. 20 µl PCR mixtures consisted of 10 µl of 2× PCR Master Mix Plus High GC (A&A Biotechnology, Poland), 0,1 µl of each primer (Sbfor, Sbrev – Genomed, Poland) at 100 µM, and 2 µl of DNA. PCR was performed in a Mastercycler ep gradient S-5345 (Eppendorf, Germany). The time-temperature profile for PCR started with initial denaturation for 3 min 94°C followed by 35 cycles of 30 s at 94°C, 30 s at 60°C, and 30 s at 72°C. The presence of specific PCR products of 223 bp was examined using electrophoresis on a 2% agarose gel and staining with ethidium bromide.

A 223-bp PCR product corresponding to *S. brevicaulis* was observed for 5/5 *S. brevicaulis* DNA samples. No PCR products were detected for *S. asperula*, *S. cinerea*, *S. fusca* reference strains, 56 other mould isolates, 65 dermatophyte isolates, 30 yeast-like isolates and one purified human DNA (100% sensitivity and 100% specificity for PCR) (Fig. 1).

Nowadays, *S. brevicaulis* identification is based on macro- and microscopic observations. As these methods are laborious, time-consuming and requiring a pure culture for correct identification, they often produce misleading results (Jagielski *et al.*, 2013). Especially diagnosis of disseminated *S. brevicaulis* infections is challenging for several reasons. First, disseminated *S. brevicaulis* infection is clinically difficult to distinguish from disseminated infection caused by

*Aspergillus*, *Fusarium* and zygomycosis. Second, in the immunocompromised organ transplant patient the sensitivity of confirmatory blood cultures is poor. There is no rapid blood test to confirm *Scopulariopsis* infection. Third, histopathologic evaluation of a cutaneous biopsy from a suspicious cutaneous lesion is not able to distinguish one disseminated mycelial infection from another. *Aspergillus*, *Fusarium* and other hyalohyphomycoses such as *Scopulariopsis* show identical morphology of biopsy specimens. To enable differentiation between the above listed mycelial fungi the tissue should be submitted for culture studies at the time of biopsy that delays the diagnosis for at least 1 week (Swick *et al.*, 2010). So far, sequencing (Jagielski *et al.*, 2013) and RFLP (Bontems *et al.*, 2009) are the only molecular methods described for *S. brevicaulis* identification. However, these methods are still laborious and time-consuming. All of these factors indicate the need for development of methods that provide simple, rapid and highly specific identification of *S. brevicaulis*. In this study we present a PCR-based method that enables specific detection of *S. brevicaulis* within few hours. Application of primers Sbfor and Sbrev in PCR gives correct results among tested isolates. This potential of the described method as the diagnostic test should be evaluated further by testing patient specimens, because the applied procedure enables DNA extraction directly from specimens thus significantly reducing the time of diagnosis (Brillowska-Dąbrowska *et al.*, 2010).

#### Acknowledgements

The authors wish to express their gratitude to A&A Biotechnology (Gdynia, Poland) for the free provision of 2× PCR Master Mix Plus High GC. The authors wish to express their thanks to Prof. B. Dworecka-Kaszak, and I. Dąbrowska, MSc from the Department of Preclinical Sciences of Warsaw University of Life Sciences (Poland), Dr Med. A. Hryniewicz-Gwóźdź, and K. Kalinowska, MSc from the Department and Clinic of Dermatology, Venereology and Allergology of Wrocław Medical University for the identification and delivery of *S. brevicaulis* isolates.

#### Literature

- Anandan V., V. Nayak, S. Sundaram and P. Srikanth. 2008. An association of *Alternaria alternata* and *Scopulariopsis brevicaulis* in cutaneous phaeohyphomycosis. *Indian J. Dermatol. Venereol. Leprol.* 74(3): 244–247.
- Besbes M., F. Makni, F. Cheikh-Rouhou, H. Sellami, K. Kharrat and A. Ayadi. 2002. Otomycosis due to *Scopulariopsis brevicaulis*. *Rev. Laryngol. Otol. Rhinol. (Bord)* 123(2): 77–78.
- Brillowska-Dąbrowska A., S.S. Nielsen, H.V. Nielsen and M.C. Arendrup. 2010. Optimized 5-h multiplex PCR test for the detection of tinea unguium: performance in a routine PCR laboratory. *Med. Mycol.* 48(6): 828–831.
- Bontems O., P.M. Hauser and M. Monod. 2009. Evaluation of a polymerase chain reaction-restriction fragment length polymorphism

- assay for dermatophyte and nondermatophyte identification in onychomycosis *Brit. J. Dermatol.* 161(4): 791–796.
- Bryuynzel I. and T.M. Starink.** 1998. Granulomatous skin infection caused by *Scopulariopsis brevicaulis*. *Acta Derm. Venereol.* 39: 365–367.
- Cuenca-Estrella M., A. Gomez-Lopez, E. Mellado, M.J. Buitrago, A. Monzon and J.L. Rodriguez-Tudela.** 2003. *Scopulariopsis brevicaulis*, a fungal pathogen resistant to broad-spectrum antifungal agents. *Antimicrob. Agents Chemother.* 47(7): 2339–2341.
- Del Prete A., G. Sepe, M. Ferrante, C. Loffredo, M. Masciello and A. Sebastiani.** 1994. Fungal keratitis due to *Scopulariopsis brevicaulis* in an eye previously suffering from herpetic keratitis. *Ophthalmologica.* 208(6): 333–335.
- Dhar J. and P.B. Carey.** 1993. *Scopulariopsis brevicaulis* skin lesions in an AIDS patient. *AIDS.* 7(9): 1283–1284.
- Endo S., M. Hironaka, F. Murayama, T. Yamaguchi, Y. Sohara and K. Saito.** 2002. *Scopulariopsis* fungus ball. *Ann. Thorac. Surg.* 74(3): 926–927.
- Filipello Marchisio V., A. Fusconi and F.L. Querio.** 2000. *Scopulariopsis brevicaulis*: a keratinophilic or keratinolytic fungus? *Mycoses.* 43: 281–292.
- Gariano R.F. and R.E. Kalina.** 1997. Posttraumatic fungal endophthalmitis resulting from *Scopulariopsis brevicaulis*. *Retina.* 17(3): 256–258.
- Gentry L.O., N.M. Nasser and M. Kielhofner.** 1995. *Scopulariopsis* endocarditis associated with Duran ring valvuloplasty. *Tex. Heart Inst. J.* 22(1): 81–85.
- Gluck O., N. Segal, F. Yariv, I. Polacheck, M. Puterman, D. Greenberg and B. Daniel.** 2011. Pediatric invasive sinonasal *Scopulariopsis brevicaulis*- a case report and literature review. *Int. J. Pediatr. Otorhinolaryngol.* 75(7): 891–893.
- Gupta A.K., C. Drummond-Main, E.A. Cooper, W. Brintnell, B.M. Piraccini and A. Tosti.** 2012. Systematic review of nondermatophyte mold onychomycosis: Diagnosis, clinical types, epidemiology, and treatment. *J. Am. Dermatol.* 66(3): 494–502.
- Hart A.P., D.A. Sutton, P.J. McFeeley and M. Kornfeld.** 2001. Cerebral phaeohyphomycosis caused by a dematiaceous *Scopulariopsis* species. *Clin. Neuropathol.* 20(5): 224–228.
- Hennequin C., M. el-Bez, J. Trotoux and M. Simonet.** 1994. *Scopulariopsis brevicaulis* otomycosis after tympanoplasty. *Ann. Otolaryngol. Chir. Cervicofac.* 111(6): 353–354.
- Issakainen J., J.H. Salonen, V.J. Anttila, P. Koukila-Kähkölä, M. Castrén, O. Liimatainen, R. Vuento, T. Ojanen, I. Koivula, M. Koskela and others.** 2010. Deep, respiratory tract and ear infections caused by *Pseudallescheria (Scedosporium)* and *Microascus (Scopulariopsis)* in Finland. A 10-year retrospective multi-center study. *Med. Mycol.* 48(3): 458–465.
- Jagielski T., K. Kosim, M. Skóra, A.B. Macura and J. Bielecki.** 2013. Identification of *Scopulariopsis* species by partial 28S rRNA gene sequence analysis. *Pol. J. Microbiol.* 62(3): 303–306.
- Jain D., J.K. Oberoi, S.K. Shahi, G. Shivnani and C. Wattal.** 2011. *Scopulariopsis brevicaulis* infection of prosthetic valve resembling aspergilloma on histopathology. *Cardiovasc. Pathol.* 20(6): 381–383.
- Krisher K.K., N.B. Holdridge, M.M. Mustafa, M.G. Rinaldi and D.A. McGough.** 1995. Disseminated *Microascus cirrosus* infection in pediatric bone marrow transplant recipient. *J. Clin. Microbiol.* 33(3): 735–737.
- Lotery A.J., J.R. Kerr and B.A. Page.** 1994. Fungal keratitis caused by *Scopulariopsis brevicaulis*: successful treatment with topical amphotericin B and chloramphenicol without the need for surgical debridement. *Br. J. Ophthalmol.* 78(9): 730.
- Migriono R.Q., G.S. Hall and D.L. Longworth.** 1995. Deep tissue infections caused by *Scopulariopsis brevicaulis*: report of a case of prosthetic valve endocarditis and review. *Clin. Infect. Dis.* 21(3): 672–674.
- Neglia J.P., D.D. Hurd, P. Ferrieri and D. C. Snover.** 1987. Invasive *Scopulariopsis* in the immunocompromised host. *Am. J. Med.* 83(6): 1163–1166.
- Phillips P., W.S. Wood, G. Phillips and M.G. Rinaldi.** 1989. Invasive hyalohyphomycosis caused by *Scopulariopsis brevicaulis* in a patient undergoing allogeneic bone marrow transplant. *Diagn. Microbiol. Infect. Dis.* 12(5): 429–342.
- Salmon A., A. Debourgogne, M. Vasbien, L. Clément, J. Collomb, F. Plénat, P. Bordigoni and M. Machouart.** 2010. Disseminated *Scopulariopsis brevicaulis* infection in an allogeneic stem cell recipient: case report and review of the literature. *Clin. Microbiol. Infect.* 16(5): 508–512.
- Satyavani M., R. Viswanathan, N.S. Harun and L. Mathew.** 2010. Pulmonary *Scopulariopsis* in a chronic tobacco smoker. *Singapore Med. J.* 51(8): 137–139.
- Stefanato C.M. and R. Verdolini.** 2009. Histopathologic evidence of the nondermatophytic mould *Scopulariopsis brevicaulis* masking the presence of dermatophytes in a toenail infection. *J. Cutan. Pathol.* 36(Suppl. 1): 8–12.
- Swick B.L., S.C. Reddy, A. Friedrichs and M.S. Stone.** 2010. Disseminated *Scopulariopsis*- culture is required to distinguish from other disseminated mould infections. *J. Cutan. Pathol.* 37: 687–691.
- Vignon M., D. Michonneau, M.T. Baixench, C. Al-Nawakil, D. Bouscary, A. Buzyn, D. Salmon and A. Paugam.** 2011. Disseminated *Scopulariopsis brevicaulis* infection in an allogeneic stem cell recipient. *Bone Marrow Transplant.* 46(9): 1276–1277.
- Wuyts W.A., H. Molzahn, J. Maertens, E.K. Verbeken, K. Lagrou, L.J. Dupont and G.M. Verleden.** 2005. Fatal *Scopulariopsis* infection in a lung transplant recipient: a case report. *J. Heart Lung Transplant.* 24(12): 2301–2304.